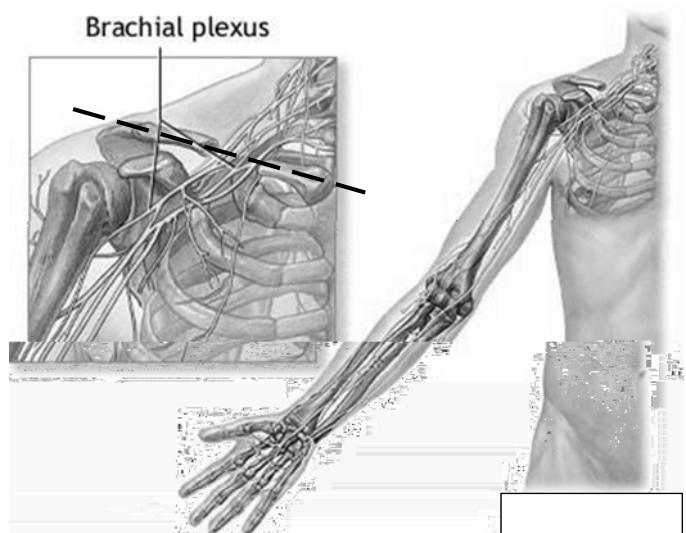


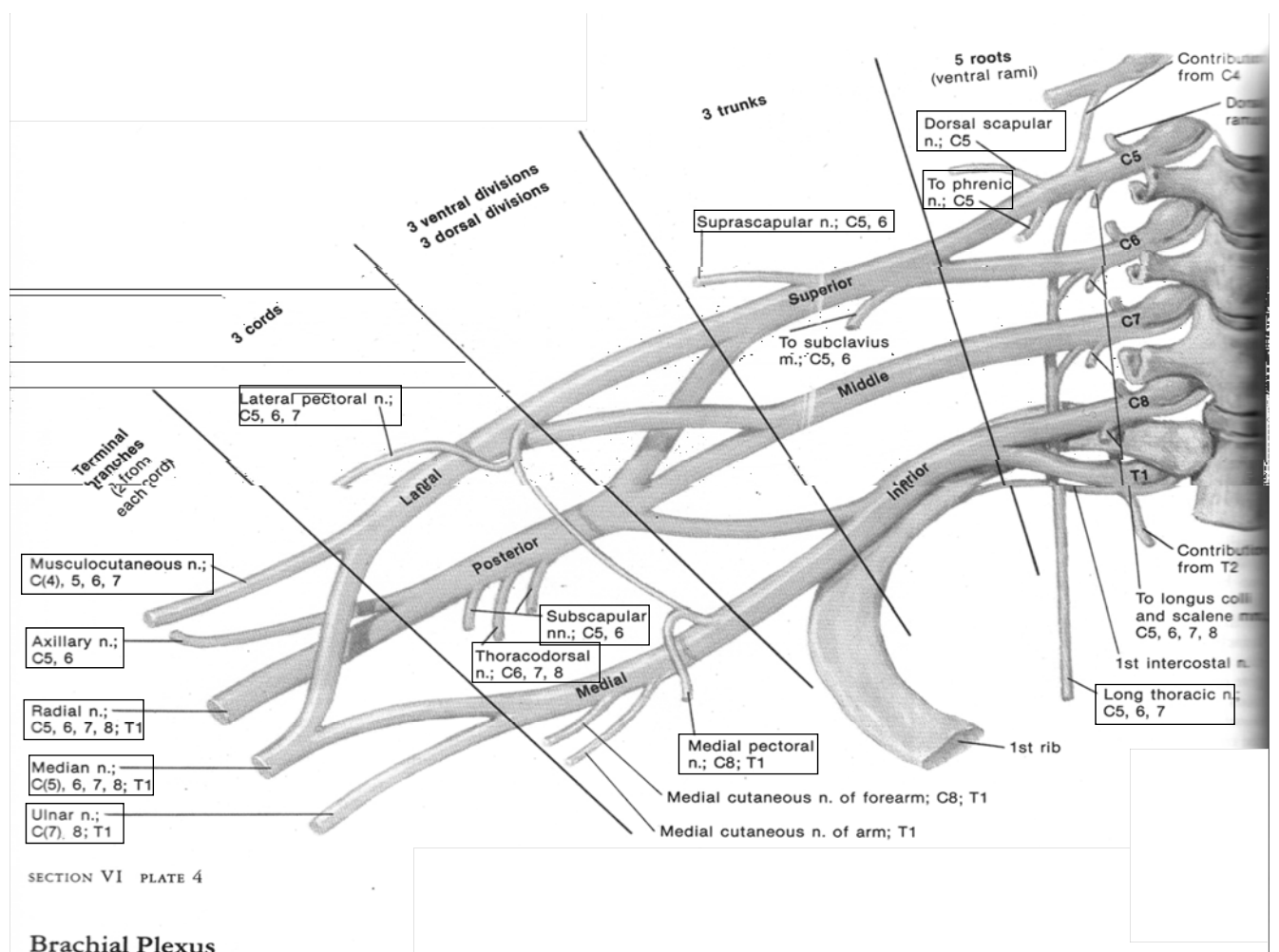
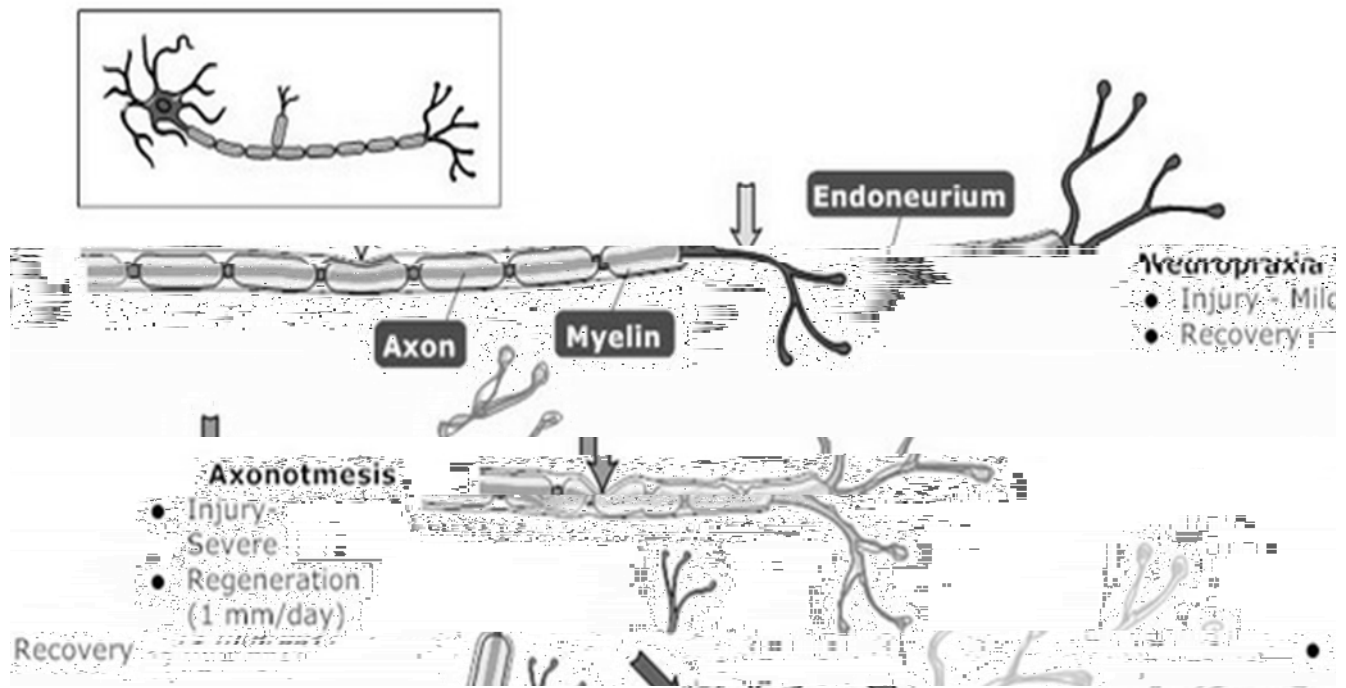
Brachial Plexus Injury

오덕원

Introduction

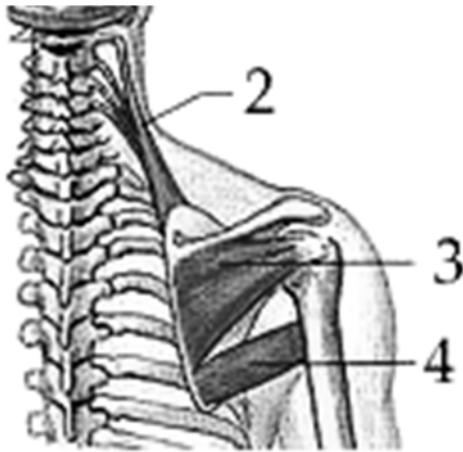
- **Supraclavicular**
 - upper plexus (C5-6) / lower plexus (C8-T1)
- **Infraclavicular**
- **Complete**
- **Incomplete**





Clinical Assessment

- Examination of individual muscle groups:



2: levator scapulae (cervical vertebrae to scapula) – elevates scapula

3: infraspinatus (lower scapula to humeral head) – lateral rotation of humerus

4: teres major (scapula to anterior humerus) – medial rotation of humerus

Clinical Assessment

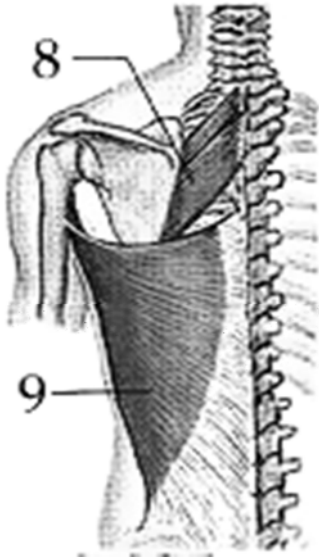
- Examination of individual muscle groups:

5: teres minor (scapula to posterior humerus) lateral rotation of humerus

6: supraspinatus (upper scapular spine to humeral head) – abducts humerus

Clinical Assessment

- Examination of individual muscle groups:

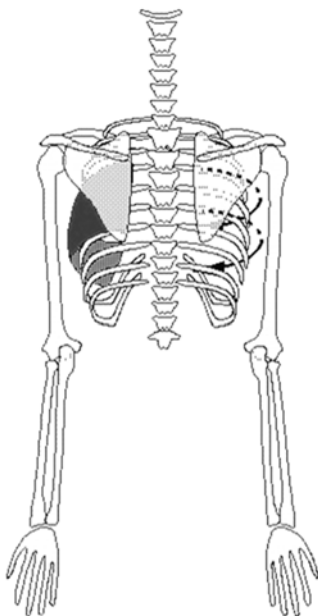


8: rhomboids (thoracic vertebrae to scapula) – raise/adduct scapula

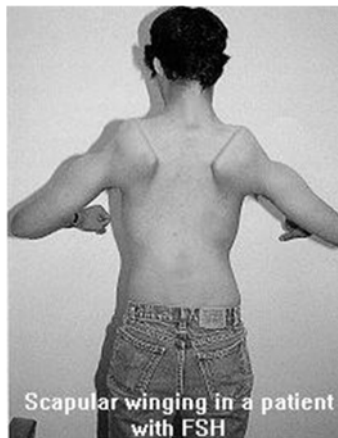9: latissimus dorsi (t-, l-, s-vertebrae to humerus) – extend/adduct arm

Clinical Assessment

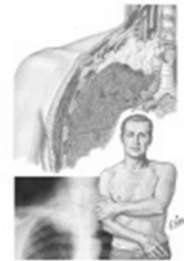- Examination of individual muscle groups:



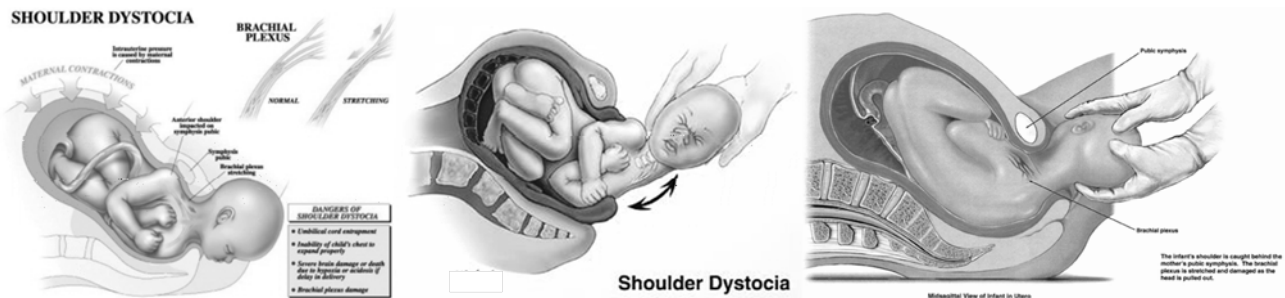
Serratus anterior (anterior surface of medial border of scapula to ribs) – protraction and rotation of scapula



Incidence



- **2-3 / 1000**
- **Dystocia (45%)**



- **Primigravida, low birth, very young pregnancy (below 20 age)**

Types of Injury

- **Traction injury**
 - **birth trauma, shoulder trauma, sports injury, motorcycle accident**
 - **shoulder dislocation due to falling down**

Types of Injury

1. Traction injury

- shoulder depression caused by excessive back load



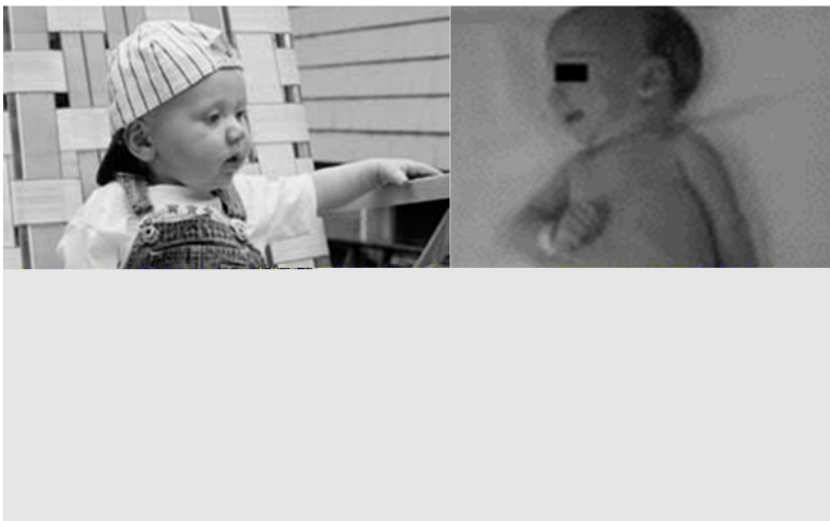
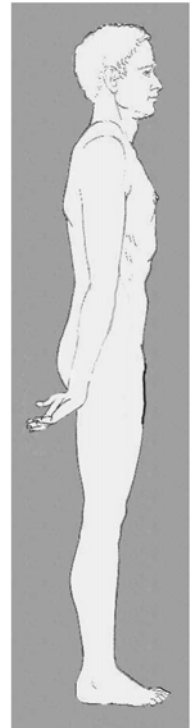Types of Injury

- Injury of nerve root
 - : paralysis of SA & Rhom.
- Supraclavicular injury > Infraclavicular injury
- Pain
 - Residual pain
 - distal < proximal

Types of Injury

2. Obstetric paralysis

- **Trend decreased with time frame**
- **Erb's Palsy**
 - **injury in upper plexus**
 - **Waiter's tip position**
 - : **shoulder ad. & int. rot.,**
elbow ext., forearm pro.,
wrist ulnar dev.
- **Klumpke's palsy**
 - **injury in lower plexus**
 - **frequently accompanied with**
the rupture of nerve root



Erb's Palsy

**Klumpke's
Palsy**



Types of Injury

3. Trauma

- Gunshot**
- Laceration injuries**

4. Iatrogenic injury